

Invia[®] Wound Therapy

Negative Pressure Wound Therapy

Clinical Evidence
and Case Reports



A comparison of various wound dressings coupled to a negative pressure wound therapy (NPWT) system to study effects on wound healing progression

Introduction

Numerous approaches have been developed to attempt to improve the process of wound healing, including applying negative pressure on the wound surface. With the introduction of new wound dressing technologies, the possibilities of combining negative pressure wound therapy (NPWT) with these new dressings may result in further advancing the quest to find improved wound therapies.

Aim

To carry out a comparison of various existing dressing types in combination with a negative pressure wound therapy system and study the influence on both wound closure and granulation tissue formation in wounds of porcine.

Methods and Results

Landras type pigs were allowed to acclimatize to the housing conditions prior to all procedures. The animals were anesthetized, shaved and scrubbed for surgery where full thickness wounds extending to the fascia over the deep back muscles (3.5cm x 3.5cm, maximal 10 per animal) were excised on each pig. The wounds were filled with various commercially available dressing types (foam, gauze 1, gauze 2, silver, textiles), and coupled with NPWT for 10 days. Each wound site was sealed with a thin air-permeable adhesive film, a flat wound drain was placed on the dressing and then connected to a vacuum source which was set to negative pressures of -10 kPa (-75 mmHg) (-20 kPa [150 mmHg] and -30 kPa [-225 mmHg], data not shown). The wound is cleansed with normal saline and dressing is changed every 2nd day. Wound measurements, histology and photographs were collected. Morphological and histological observations indicate that healing is taking place taking place with all dressing types used in combination with NPWT. Giving insights that combining NPWT with different types of dressings provides efficient healing in porcine wound models.

Figure 1: Histology of wounds with and without NPWT at 10 days

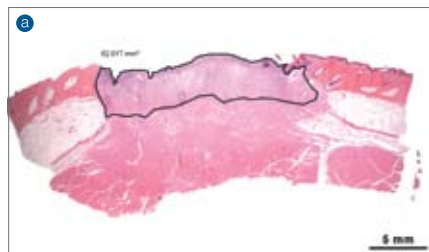


Fig.1A
Histology of wound treated with NPWT for 10 days (wound dressed with moist gauze, dressing changed every 2nd day and continuous negative pressure -10kPa (75mmHg) applied)

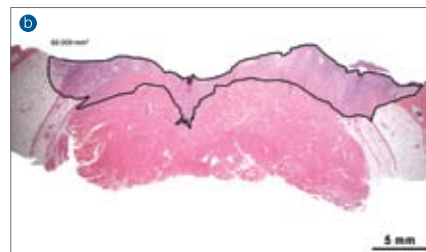


Fig.1B
Histology of wound treated without NPWT for 10 days (wound dressed with moist gauze, dressing changed every 2nd day).

Granulation tissue formation observed in both wounds, however wound treated with NPWT shows a marked wound edge and wound area reduction (Fig.1A gauze with NPWT) when compared to wound treated with gauze alone (Fig.1B gauze without NPWT). Figures A and B are H&E-stained sections. (Original magnification x 0.5, scale bar = 5mm).

Figure 2: Histology of wounds treated with various dressings coupled with NPWT at 10 days

Histology of wounds at 10 days and treated with various dressings (A) Gauze I*, (B) Black Foam**, (C) Silver***, (D) Textile**** and (E) Gauze II***** all coupled with NPWT (-10kPa). (F) Appearance of Control wound without NPWT (wound is cleansed every 2nd day as well as other treatments, and only a thin air-permeable adhesive film is applied). Wounds from all treatments presented with varying

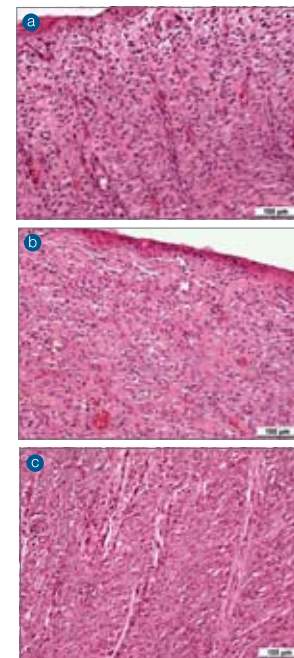


Figure 3: Wound area measurement

The area of wound healing is measured by an imaging program (Leica Microsystems, Leica IM 1000 Professional image management system, Stereo microscope [Leica MZ16] and Camera [Leica DC480], Heerbrugg, Switzerland). The area where tissue granulation is evident was measured accordingly. (Original magnification x 0.5, scale bar = 5mm).

Notes:

- * Invia® Wound Therapy for NPWT, Medela AG, Baar, Switzerland
- ** V.A.C.® Therapy Systems, KCI, Texas, U.S.A.
- *** Actisorb® Silver 220, Johnson & Johnson Medical Ltd, Skipton, U.K.
- **** 3 mesh®, Müller Textil GmbH, Germany
- ***** Derma Sciences, Princeton, NJ, U.S.A.

Presented at the 22nd Annual Symposium on Advanced Wound Care & Wound Healing Society (SAWC/ WHS), Dallas, Texas, USA, April 26-29, 2009

Conclusions

Results suggest that healing is taking place with each one of the dressings used in combination with NPWT on the porcine wound model. All new regenerated tissues appeared healthy with collagen and new vessel formation, indicating good response of the wound to the

degrees of collagen and new small vessel formation. Proliferation of cells in the wound bed was evident in all the treatments (PCNA stains, data not shown). Inflammatory cells were sparsely spread throughout the wound bed from all of the treatments. Control wound appears to have a severe and extensive acute suppurative inflammation dispersed throughout the surface of the granulation tissue. In addition, Control wound presents with moderate focal hemorrhage and a general erythematous appearance on the wound surface. (A to F) are H&E-stained sections. (Original magnification x 20, scale bar = 100 µm).

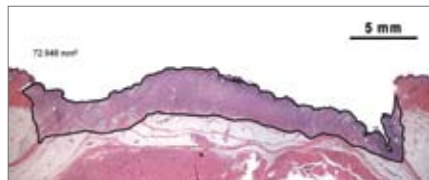
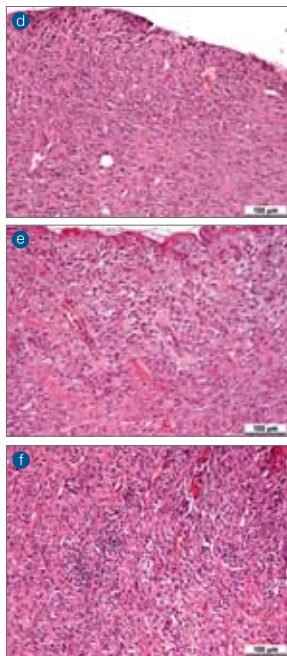


Figure 4: Comparison of wound area from various dressing treatments coupled with NPWT

Photographs of wound area at 10 days treated with various dressings (A) ,Gauze I^{**}, (B) ,Black Foam^{***}, (C) ,Silver ^{****}, (D) ,Textile^{*****} and (E) ,Gauze II^{*****} all coupled with NPWT set with negative pressure -10 kPa (-75 mmHg). (F) Measurement of ,Control' wound without NPWT, H&E-stained section (Original magnification x 0.5, scale bar = 5mm).

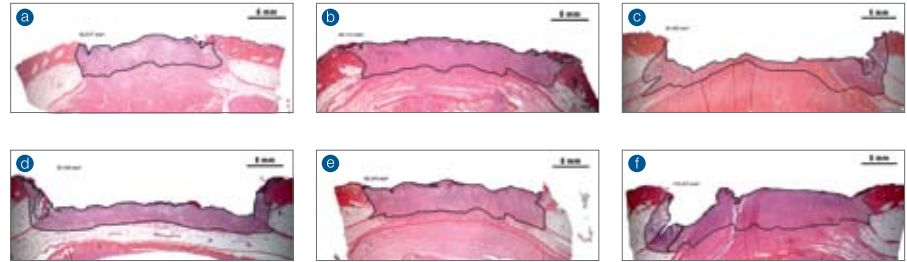
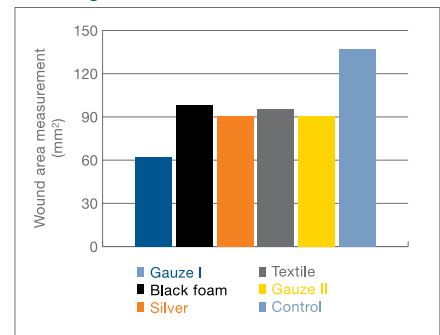


Figure 5: Extent of wound area reduction at day 10 from various dressing treatments coupled with NPWT

Measurement of wound area at 10 days treated with various dressings ,Gauze I^{**} ,Black Foam^{***} ,Silver ^{****} ,Textile^{*****} and ,Gauze II^{*****} all coupled with NPWT set with negative pressure -10 kPa (-75 mmHg). Measurement of ,Control' wound without NPWT.

Wound Area Measurement from Various Dressings + NPWT

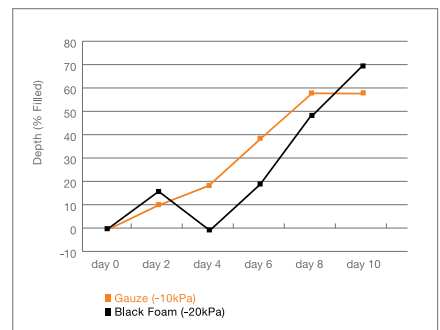


treatment applied. Although healing was observed in the control wound, the morphological and histological analysis clearly shows the tissue is unhealthier in appearance when compared to other treatments combined with NPWT.

Figure 6: Performance at Clinically Recommended Pressure Levels

Measurement of wound filling over time (10 days). Wounds were treated with ,Gauze I^{**} or ,Black Foam^{***} all coupled with NPWT. Depth (% filled) was measured every 2nd day until experiment end. In the figure on the right, two NPWT systems currently available on the market have been compared within the range of their clinically recommended pressure levels, gauze (-10kPa, -75mmHg) and foam (-20kPa, -150mmHg); they exhibited clinically comparable 10-day healing rates. The implication of this research is that numerous clinically-effective alternatives exist, each having its own set of unique advantages (i.e. cost, ease-of-use, pain management).

Performance at Clinically Recommended Pressure Levels



Invia® Wound Therapy Case Report: Dehisced Abdominal Wound

Patient History

- 63 year old female
- Hypertension
- Hyperthyroidism
- Morbid obesity
- Admitted to an acute care facility with a ruptured aortic aneurysm and a splenic artery tear

Surgeries:

- Ligation and repair of splenic artery, removal of aortic aneurysm, splenectomy, tracheostomy
- Returned to operating room for repair of transverse colon secondary to necrotic bowel and abdominal compartment syndrome
- Colostomy

Treatment History:

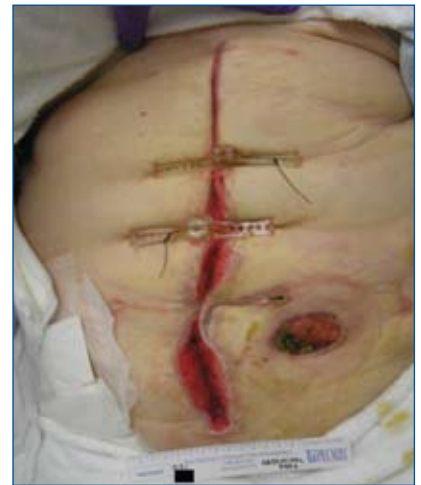- KCI® V.A.C.® for NPWT placed at -125mmHg, in use 4 days only
- Deep vein thrombosis treatment
- Invia® Wound Therapy initiated

Treatment Goals

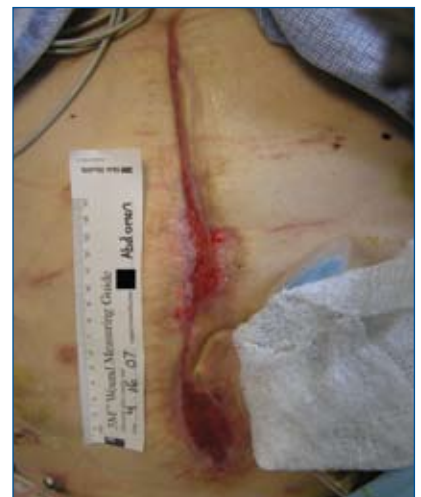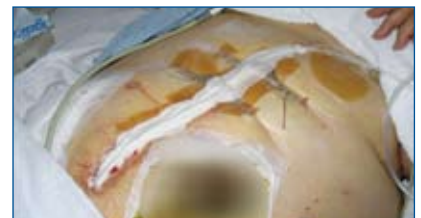- Increase granulation tissue formation
- Reduce risk of infection
- Decrease pain associated with dressing changes
- Protect periwound from trauma related to multiple operative procedures
- Allow for moist healing environment
- Allow for transition to topical moist dressing

Clinical Outcomes

- 100% granulation tissue present in wound
- 80% decrease in wound volume
- Decreased patient pain
- Allowed transition to hydrogel dressings until complete wound closure
- Patient discharged to acute rehabilitation facility for physical therapy and wound care

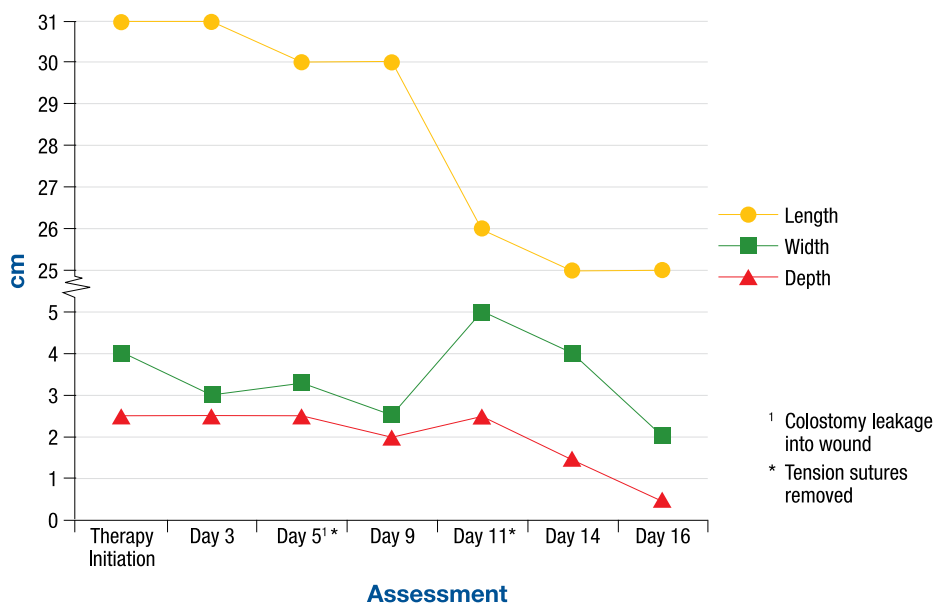


Day 1



Day 16

Wound Measurements



Invia® Wound Therapy Case Report: Amputation with Ulceration

Patient History

- 55 year old male
- Insulin-dependent diabetes mellitus
- Hypertension
- Decreased sensory function and impaired mobility
- Lisfranc dislocation of the foot
- Charcot arthropathy of the mid and rear foot

Surgery:

- Symes amputation

Complications:

- Chronic non-healing wound to amputation site.
- Infection extending to the bone resulting in two areas of dehiscence

Treatment History:

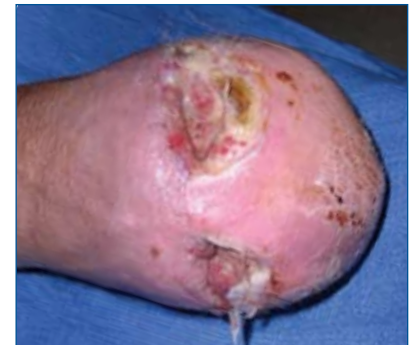- Invia® Wound Therapy initiated

Treatment Goals

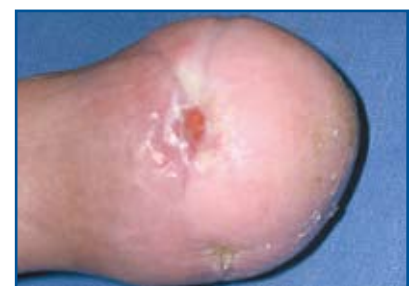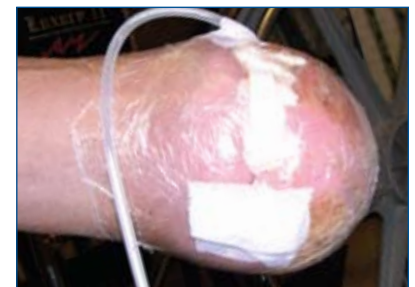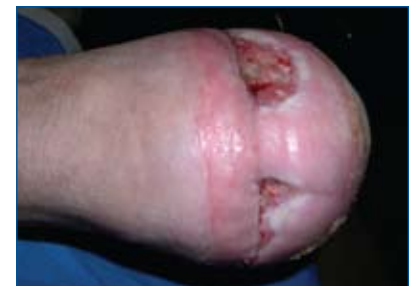- Promote moist wound healing environment
- Promote granulation tissue formation and conversion to a superficial wound
- Reduce risk of infection and promote limb preservation

Clinical Outcomes

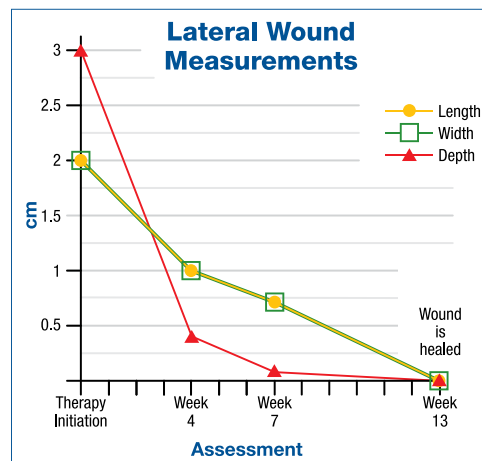
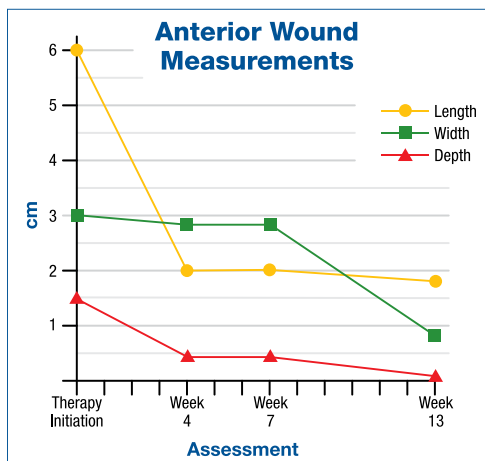
- Increased granulation tissue
- 90% reduction in wound volume
- Decreased wound exudate
- Patient transitioned to hydrogel dressing that could be changed every other day in the home



Initiation of Invia wound therapy



Post therapy



Invia® Wound Therapy Case Report: Abdominal Wound

Patient History

- 28 year old male
- Head trauma
- Femur fracture
- Multiple rib and sternal fractures
- Splenic artery injury
- Deep vein thrombosis
- Mesenteric hematoma
- Peritonitis

Surgeries:

- Multiple exploratory laparotomies
- Splenectomy
- Anastomosis and end-colostomy placement
- Ventral hernia repair with mesh
- Escharotomies to bilateral lower extremities with split thickness skin grafts

Treatment History:

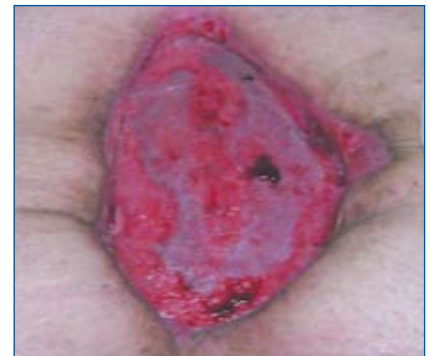- KCI® V.A.C.® for NPWT placed on patient after initial surgical procedure
- V.A.C.® discontinued
- Skilled nursing facility for rehabilitation
- Invia® Wound Therapy initiated

Treatment Goals

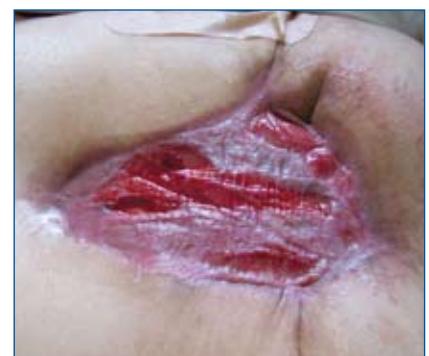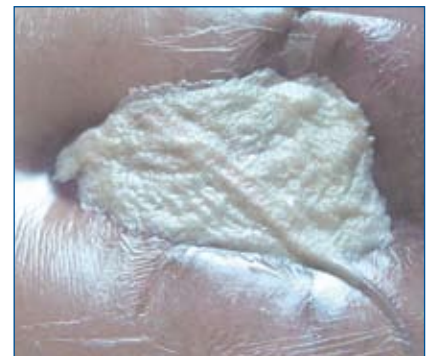- Reduce risk of infection and septicemia with chronic non-healing wound status
- Promote granulation tissue formation
- Increase patient comfort during dressing changes
- Reduce risk of trauma and damage to abdominal granulation tissue during dressing changes
- Control odor

Clinical Outcomes

- 100% granulation tissue formation to wound bed
- 97% decrease in total wound volume
- Minimal drainage without odor
- Discomfort during dressing change was minimized
- Wound transitioned to a hydrogel dressing that could be performed by patient's family, facilitating discharge from skilled-care facility

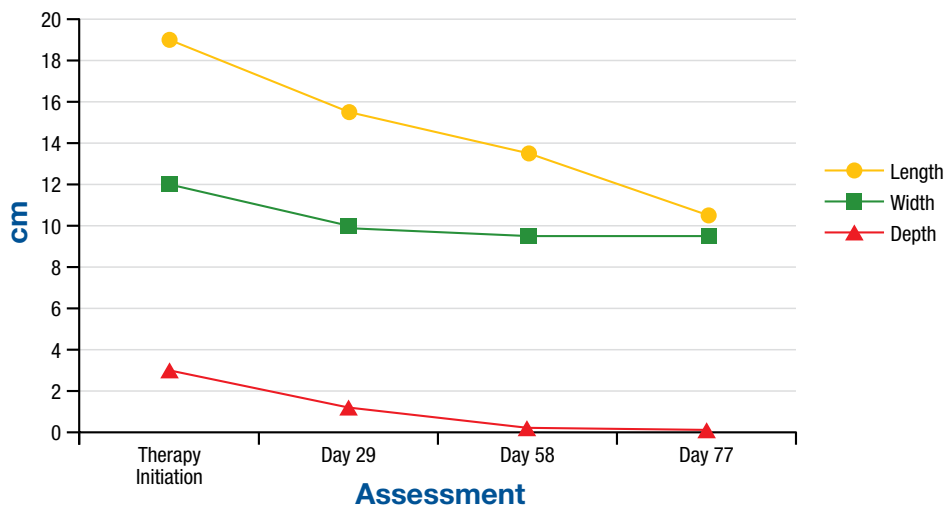


Day 9



Day 77

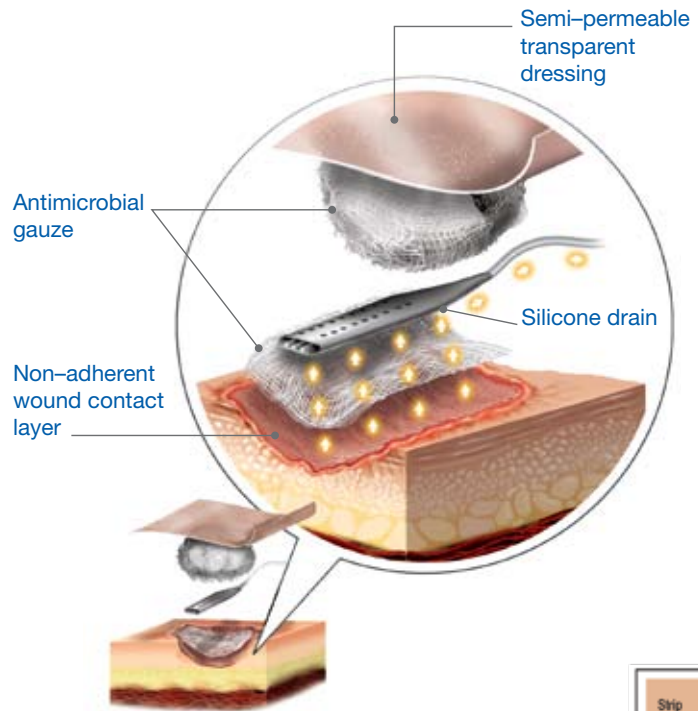
Wound Measurements



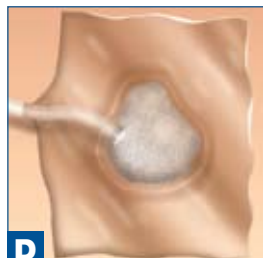
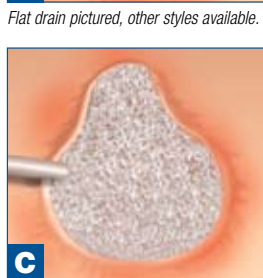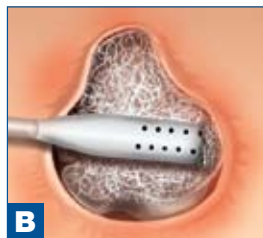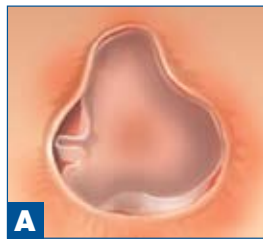Invia® Wound Therapy

Instructions for Use

Please keep in mind that each wound is unique and must be assessed by a qualified medical professional who must use his or her best judgment when applying this therapy.



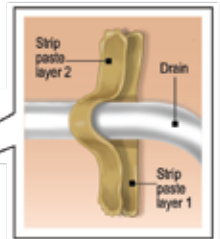
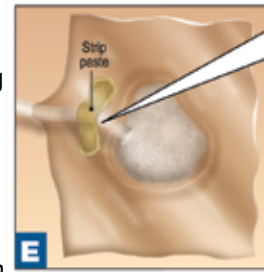
1. Inspect the kit for completeness and ensure there is no damage to packaging or individual items within the kit.
2. Cleanse wound and periwound area according to institution guidelines or physicians orders. Irrigate the wound thoroughly with saline and gently wipe away any excess fluid with sterile antimicrobial gauze.
3. Prep the skin up to 2 inches around the wound bed using the Cavilon™ skin sealant. Allow to dry.
4. Cut non-adherent wound contact layer to mimic the size and shape of the wound bed. Cover the entire wound bed with the non-adherent dressing. (see illustration A)
5. Saturate single layer of antimicrobial gauze with saline and place into the wound bed.
6. Trim the drain so it is confined to the wound bed and place it directly on top of the antimicrobial gauze in the wound. Ensure that the drain is at least 1–2cm from the edge of the wound and is not in a fistula tract. (see illustration B)
7. Saturate additional antimicrobial gauze with saline, open and fluff into the wound to completely cover the drain and fill the wound with antimicrobial gauze to skin level. (see illustration C)
8. Cut transparent dressing 2 inches beyond the packed wound bed on each side.



Flat drain pictured, other styles available.

Note: If you are treating two wounds simultaneously, a Y-connector is available from Medela.

9. Create an airtight seal by applying the transparent dressing starting with the side opposite the tubing. Adhere the dressing firmly to the entire wound site. When you reach the tubing, you may lift it up and squeeze the dressing around and under the tube to create an airtight seal. Do not place over bony prominences.
10. Press the dressing down firmly around the entire wound to ensure the wound environment is sealed. (see illustration D)
11. Strip paste may be used to comfortably affix tubing and to promote a good seal, while protecting the integrity of the skin. (see illustration E)
12. Connect the drain tubing to the suction tubing using the “Christmas Tree” connector.
13. If you are using the Invia® Vario connect the suction tubing to the Medela canister.
14. If you are using the Invia® Liberty connect the suction tubing to the Liberty pump, and click the canister in place on the side of the pump.
15. Set the Invia® Vario or Liberty to constant suction between -60 to -80mmHg or as directed by your physician. When the suction is applied, the dressing should contract noticeably. If the dressing does not contract, the system may not be sealed. Inspect the dressing and reseal if necessary.
16. Latex-free, hypoallergenic surgical tape may be used to window pane transparent dressing and affix drainage tubing as necessary.
17. Dressing changes are recommended every 48–72 hours unless otherwise directed by a physician.
18. Routinely check that the vacuum level is set as prescribed and that the dressing is properly sealed. Check more often as needed.



<p>Indications:</p> <p>Medela® Invia® Wound Therapy is indicated to help promote wound healing, through means including drainage and removal of infectious material or other fluids, under the influence of continuous and/or intermittent negative pressures, particularly for patients with chronic, acute, traumatic, subacute and dehisced wounds, partial-thickness burns, ulcers (such as diabetic or pressure), flaps and grafts.</p> <p>The types of wounds indicated are:</p> <ul style="list-style-type: none"> • Diabetic/Neuropathic ulcers • Pressure ulcers • Chronic wounds • Acute wounds • Dehisced wounds 	<p>Contraindications:</p> <p>Contraindicated for patients with:</p> <ul style="list-style-type: none"> • Malignancy of the wound • Untreated osteomyelitis • Non-enteric and unexplored fistula • Necrotic tissue with eschar present • Do not place Invia® Wound Therapy dressing over exposed blood vessels or organs. 	<p>Warnings:</p> <p>The following Warning statements describe the potential for serious consequences to the patient, such as death, injury, or adverse reactions.</p> <ul style="list-style-type: none"> • Failure to read and follow all procedures in the Instructions for Use manual prior to use may result in death or injury of the patient. • The Instructions for Use provides general guidelines for the use of Invia® Wound Therapy; however, the safe and effective operation of this device requires specific instruction from a physician. • Failure to obtain consent and any additional instructions from the treating physician prior to use may lead to death or injury of the patient. • Serious injury or death can result from bone fragments or sharp edges (e.g., staples or hardware) that could puncture protective barriers, vessels, or organs. • Please consider using a protective barrier where drain tubing comes in contact with patients with fragile or pliable skin. 	<p>Precautions:</p> <p>The following statements describe medical conditions that may require special care for the safe and effective use of Invia® Wound Therapy.</p> <p>Additional precautions must be used with:</p> <ul style="list-style-type: none"> • Patients taking anticoagulants or platelet aggregation inhibitors, or in patients experiencing active bleeding or difficult wound hemostasis • Wounds that involve a fistula (excluding contraindicated fistulae) • Using Invia® Wound Therapy in close proximity to blood vessels and organs (provide necessary protection of all vessels and organs using a protective barrier) • Patients with a history of irradiated or sutured blood vessels or organs • Wounds that involve tunnels or sinus tracts <p>Medela® makes no assurances as to the efficacy of Invia® Wound Therapy.</p> <p>Contact the Medela® customer assistance department for help with product operations.</p> <p>Not available in all countries.</p>
---	--	---	--

Federal law restricts this device to sale or rental by or on the order of a physician.



Medela, Inc., P.O. Box 660, 1101 Corporate Drive, McHenry, IL 60051-0660
 Phone: 877-MY INVIA (877-694-6842) Fax: 815-363-2487
 Email: myinvia@medela.com www.medela.com

Medela and Invia are registered trademarks of Medela, Inc. Vario and Liberty are trademarks of Medela, Inc.
 KCI and V.A.C. are registered trademarks of KCI Licensing. Actisorb is a registered trademark of Johnson & Johnson Medical Ltd, Skipton, U.K.
 3 mesh is a registered trademark of Müller Textil GmbH, Germany. Derma Sciences is a registered trademark of Derma Sciences, Princeton, NJ, U.S.A.